

# Pathophysiology of binocular vision and amblyopia

Joseph Lang, MD

University Eye Clinic, Zurich, Switzerland

Stable monocular and binocular vision and orthotropia are the prerequisites of the highest form of binocular vision, namely stereopsis. There are natural tests for examining stereopsis such as the three-rod test or the two-pencil test. Haploscopic tests are believed to deal with stereoscopy. Natural stereopsis is better with large interpupillary distance. In haploscopic tests, the results differ between contour stereotests and random-dot situations and from degeneration experiments in the visual cortex, a new hypothesis on anomalous retinal (cortical) correspondence is proposed. Different forms of strabismus are discussed.

Current Opinion in Ophthalmology 1993, 4;V:2-9

Before dealing with the pathophysiology of binocular vision, we should discuss normal binocular vision. This is best done with an example.

## Monocular visual direction

A church with adjacent trees serves as a fixation object (Fig. 1). Attention is directed to the church tower. What time is it? On the retina (Fig. 2), this picture is reversed vertically and horizontally. The object of fixation, *ie*, the church tower clock, is projected onto the point of sharpest vision—the foveola. The other objects appear on the retina on either side of the foveola at given distances. Each retinal point, or more precisely each retinal area, has a directional value. The foveola has the direction of "straight ahead"; with the foveola, we look directly at an object. The other retinal points form the surrounding directions. A point beneath the fovea has the directional value of "just above" straight ahead. A point nasal to the foveola has the directional value of "temporal from straight ahead."

## Binocular vision

Cooperation between the two eyes is based on the fact that the visual fields of each eye overlap ex-

actly, and that in each eye, points or areas with the same visual direction exist (with the exception of the monocular temporal halfmoons). For example, the two foveolas have a common visual direction and also a point 2.5° nasally in the right eye and temporally in the left eye. These points are called corresponding retinal points.

## Retinal and cortical correspondence

In the past, retinal identity, *eg*, Hering's law of retinal identity, or retinal congruence was referred to by clinicians; now we speak about retinal and cortical correspondence (RC). Correspondence of retinal points is a cortical function. A simple way to experience RC is to fixate a light with one eye and to project the star of an ophthalmoscope into the other eye. When the light and the star are seen superimposed, each object is imaged on the foveola of one eye.

## Optic nerve and chiasma

The sensations of 126 million rods and cones of each eye are conducted through the bottleneck of only 1 million fibers of the optic nerve to the chiasma. In the chiasma, the fibers of the nasal retina decussate, whereas the fibers of the temporal retina are uncrossed. Then, they form, along with the

---

### Abbreviations

ARC—anomalous retinal correspondence; RC—retinal and cortical correspondence.

homonymous contralateral fibers, the tractus opticus to the corpus geniculatum laterale (Fig. 3).



Fig. 1. A church with adjacent trees serves as a fixation object.

Regarding the chiasma, in all vertebrates below mammals, the decussation of the optic nerve fibers at the chiasma is complete. In higher primates, about two thirds of the fibers cross, and it is only in humans that half of the fibers, *ie*, those of the nasal retina, are crossed and the other half of the temporal retina is uncrossed. In addition, in the early stages of human development, the primitive phylogenetic arrangement of complete decussation of the optic nerve fibers occurs at the chiasma. It is not until the 11th week of gestation that uncrossed fibers begin to appear [1].

## Second visual pathway

Before arriving at the corpus geniculatum laterale, approximately 20% of the fibers of the tractus travel to the colliculus superior and to the pretectal region, *eg*, the fibers for pupillary reflexes, and from there to the pulvinar and to the cortex associativus [2] (Fig. 3). These fibers are crossed in the chiasma. Again, we should remember phylogenesis; in lower vertebrates, the roof of the midbrain (tectum opticum) contains visual and oculomotor centers and receives the mass of optic fibers. In birds, the dorsal area of the midbrain is of immense importance. In mammals, however, the anterior colliculi and the tectum are much reduced and most of the optic fibers terminate in the corpus geniculatum laterale, where they are relayed by the radiatio optica to the occipital cortex.

Two visual pathways must be differentiated: 1) the phylogenetic older pathway to the tectum opticum; and 2) the phylogenetic younger retino-geniculostriate pathway to the corpus geniculatum laterale and from there to Brodmann's area 17 in the cortex. In the corpus geniculatum laterale and in the cortex, magnicellular neurons for motion and parvicellular neurons for detection of details are found.

The work of Hubel and Wiesel [3] has shown that binocular vision does not yet occur in layer IV of area 17 in the cortex, but does occur outside of this layer where the so-called binocular cells are to be found.

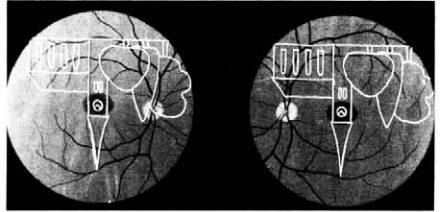


Fig. 2. Projection into the fundi with orthotropia. The object of fixation is projected onto the foveola.

## Cortical enlargement

In the cortex, there is a topical representation of the retina, but the central retinal area, especially the fovea, is enlarged. According to some authors, the foveola (with a diameter of 0.3 mm on the retina) is enlarged in the cortex by 120 times to 36 mm, whereas an area outside of the fovea of the same diameter is enlarged only 14 times. This finding corresponds to the retina where in the center, the relation between cones and nerve fibers is almost one to one, whereas in the retinal periphery, the sensation of about 100 rods converges to one nerve fiber. These facts are very important when later discussing anomalous RC.

## Stereopsis

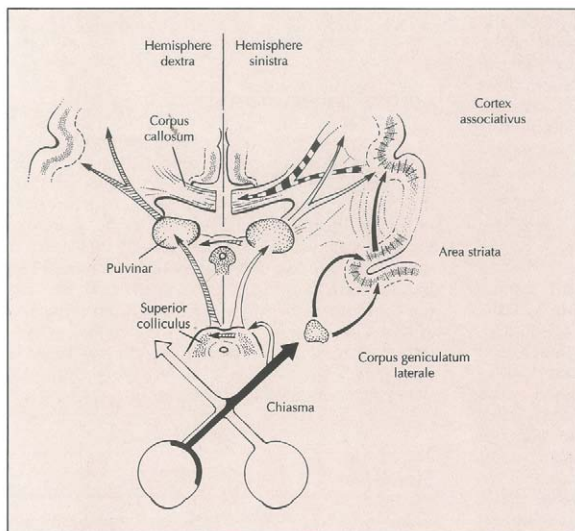
Although stereopsis is rather "an epiphenomenon of binocular vision," I believe that stereopsis is the highest performance of binocular vision [4]. There are helpful clues for monocular stereopsis, *eg*, the size of the object, perspective, light and shade,

and the phenomenon that the nearer object may cover the distant object. Only binocular parallax allows exact assessment of depth perception close up. I would like to present two tests of stereopsis, *ie*, a natural and very simple two-pencil test and a haploscopic modern test, the Lang stereotest. Both of these can be performed very quickly [5].

With the two-pencil test, the patient holds a pencil with the blunt end down and by using a slow vertical movement, attempts to touch a second pencil held at eye level by the examiner with the blunt end up. First, the patient attempts this test with both eyes open; then the patient tries it with the nonleading eye closed. In this way, the ability to meet a target is compared under monocular and binocular conditions. It is amazing how much even a squinting and amblyopic eye helps with stereopsis. We can even assess whether anomalous RC helps binocular stereopsis. The two-pencil test is a natural test and corresponds very well to daily life conditions, *ie*, when pouring wine into a glass [6•]. We must differentiate between natural tests (stereopsis) and haploscopic tests (stereoscopy). In natural situations, stereopsis is better with large interpupillary distance, whereas with haploscopic devices (stereoscopy), depth perception is better with a small interpupillary distance [6•].

The Lang stereotest is a haploscopic, random-dot test for stereoscopy that has the advantage that no red-green or polarized eyeglasses are necessary [5]. The haploscopic device consists of cylinder gratings (Fig. 4). There are more than 20 plano cylinders to each centimeter and under each cylinder there are two random-dot pictures—one seen with the right eye; the other seen with the left eye. In three locations the form of a star, a cat, and a car are shifted horizontally. With monocular vision only random dots are seen, whereas with normal binocular vision, a stereoscopic picture of these three objects is visible. Because eyeglasses are not necessary and three objects are seen, one can, even in preverbal children, diagnose stereopsis when the patients shift their fixation from one object to another, when the patients point to the objects, or when the patients try to grasp the objects. Of course, this is successful only in watchful and attentive babies.

An example may best show the advantage of this test. One patient at birth showed a paralysis of the left lateral rectus, that disappeared at the age of 2 months. The eyes were then orthotropic. At age 6 months minus 3 days, the patient reacted without any doubt to the stereotest.



**Fig. 3.** The second visual pathway to the colliculus superior, pulvinar, and to the cortex. (From Trevarthen and Sperry [2]; with permission.)

From this example we may learn that at age 6 months, monocular vision must be very well developed to assess and distinguish the small random dots. We must also acknowledge that there are children in whom binocular vision and stereopsis is present at such an early age. Furthermore, we may learn that strabismus present up until age 2 months does not preclude normal binocular vision from developing later.

This finding confirms an article in which five neonates had palsy (four palsies of the VIth nerve, one palsy of the IIIrd nerve), one had retinal hemorrhages, and another had lid hematoma at birth. These abnormalities resolved within 6 weeks and the children have developed normal visual acuity, motor fusion, and stereopsis. It was concluded that there is a latent period of 6 weeks before the onset of the sensitive period [7].

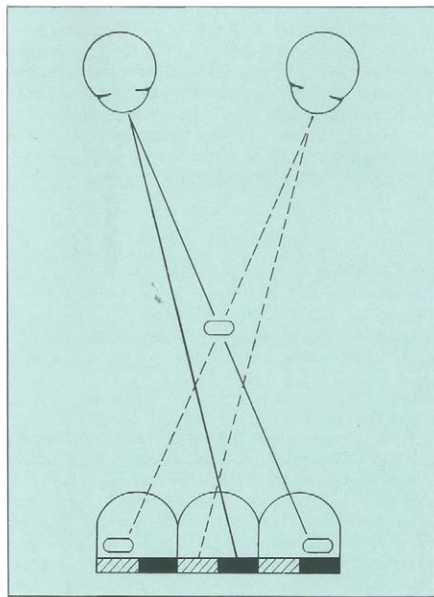


Fig. 4. The haploscopic device consists of cylinder gratings, as shown.

The differences between contour stereotests such as the Titmus test and random-dot stereotests have

been emphasized in three articles [8,9,10\*\*]. One of the articles dealt with differentiation between monofixators and bifixators; another article dealt with differentiation of anisometropias from microtropias as well as their importance for differentiating normal from anomalous correspondence. Patients with anisometropic amblyopias may pass random-dot stereotests, whereas patients with microtropias usually do not pass. Patients with both conditions pass contour stereotests.

None of 42 children who passed the Lang stereotest under binocular conditions were able to pass it monocularly [10\*\*]. Formerly, it was believed that stereopsis could function only after the form or gestalt of an object had been recognized. With random dots (in contrast to contour stereotests) it becomes clear that stereopsis is processed in the brain before forms are recognized [11].

### Strabismus

In manifest strabismus, the visual axis of only one eye is directed at the object of fixation, while the other eye deviates. With normal binocular vision, the tower clock appearing on the nasal side of the papilla has the directional value of "on the left from straight ahead." A patient with normal binocular vision sees two church towers—one straight ahead and the second to the left—thus, the patient has diplopia. At the same time, the tower clock is partly superimposed by a tree. If the patient sees two objects at the same place, that means that the patient has confusion. To overcome such a troublesome situation, two mechanisms exist, *ie*, suppression and anomalous retinal correspondence.

### Suppression

Panum [12] showed suppression or retinal rivalry with opposite diagonal lines. Binocularly, these lines are not fused, but are suppressed in the fashion of a mosaic. Suppression is a current mechanism in daily life. An example familiar to all of us is suppression of the nonfixating eye in monocular microscopy. Squinting children very quickly react to double vision with suppression, which then, if monocular, leads to amblyopia. In a convergent strabismus of 15°, the papilla forms a natural suppression zone of 5°, which is enough to hide more than one full moon and to avoid diplopia.

## Amblyopia

Amblyopia is an impairment of vision without visible ocular damage. The most important form is strabismic amblyopia, due to suppression in unilateral strabismus. Another important form is anisometropic amblyopia due to a refractive error in one eye. Both forms may be combined such as glaucoma and maculopathy may be combined. Other forms are less important. Experimental deprivation amblyopia in animals is somewhat different.

In the diagnosis of amblyopia, checking fixation of the eye is most important by projecting the fixation star of an ophthalmoscope on the retina. Besides direct ophthalmoscopy, indirect ophthalmoscopy can be used, projecting a fixation mark through a lens into the fundus. For this purpose, I prefer to use a larger, round fixation mark that covers the center of the fovea. The circular border reflex of the fovea makes evaluation of fixation easy. Because the center of the fovea is covered, the patient is not dazzled and the pupil is not too contracted.

The most efficient treatment of strabismic amblyopia is occlusion at a young age. The most effective way of dealing with anisometropic amblyopia is correction with glasses.

Curiously enough, in an article on microtropia versus anisometropic amblyopia, the diagnosis of microtropia has not been made by ophthalmoscopic examination for fixation and for anomalous correspondence, but just on the basis of the 4-D prism test [13\*].

## Anomalous retinal correspondence

We can define anomalous retinal correspondence (ARC) as a situation when noncorresponding retinal points have the same sense of visual direction. The sensory direction of the deviating eye is displaced according to the angle of deviation. The subjective "straight ahead" sensation for the deviating eye is no longer at the fovea, but where the fixation object is imaged. The fovea of the right eye and a location nasal to the papilla of the left eye have the same visual direction. The change takes place with the whole visual field of the deviating eye, but the center of ARC may be suppressed (fixation-point scotoma). We can state that an ARC exists in about 85% of the cases of con-

vergent squint, mostly combined with some sort of suppression.

The advantage of ARC over suppression lies in the fact that some useful binocular vision, even some gross stereopsis is present. This can be shown by the two-pencil test.

## Diagnosis

Diagnosis can best be made by ophthalmoscopic examination of correspondence. This is also the best way to familiarize oneself with this sensory phenomenon. The patient fixates the light on the Maddox prism with one eye. At the same time, the investigator views the fundus of the other eye through a direct ophthalmoscope and projects a star onto the fovea of this eye. The patient must now indicate whether the star is seen on the fixation light or next to it. If the star is not seen on fixation light, then the two foveae have a different direction sense and ARC is present. The location on the Maddox prism where the star is seen gives the angle of anomaly. To find the center of anomaly, one can displace the star until it is seen on the fixation light. I use a periscope like a double mirror. In this way, the examiner's head does not obstruct the view of the fixation light. I have also developed a photographic method to show ARC [14].

## New hypothesis

The basis of ARC is situated in the brain. I would like to advance a new hypothesis for ARC based on the results of stereotests, retinal topography, and degeneration experiments in the brain (Fig. 5).

Let us first compare the results of the two-pencil test with contour (Titmus) and with random-dot (Lang) stereotests [15\*]. We have found that in cases of amblyopia ex anisometropia, patients may even recognize random-dot stereotests; in cases of microtropia, patients are usually negative with random-dot stereotests, but positive with contour stereotests. Subjects with large angles with harmonious ARC may pass the two-pencil test with deep amblyopia but do not recognize contour or random-dot stereotests.

By means of degeneration experiments, it has been shown that from Brodmann's area 17 to areas 18 and 19, and further to areas 20 and 21 of the inferotemporal cortex, there are many stages of visual



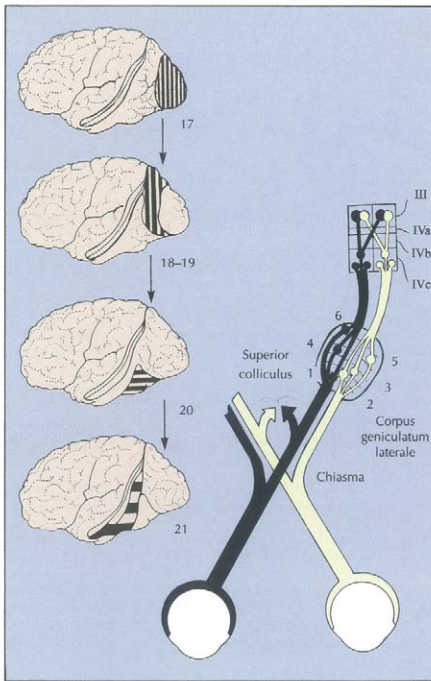


Fig. 5. Visual pathways to chiasma, corpus geniculatum laterale, and area striata and from the area striata to the inferotemporal areas.

data processing [16]. It is also known that retinal topography becomes increasingly less exact along these projections. Additionally, there are neurons in the inferotemporal cortex with large receptive fields encompassing the midline of the retina and the corpus callosum. It has also been shown that the neurons of the inferotemporal cortex react to complicated visual structures, such as a hand [17].

Normal RC of a high degree and fine stereopsis takes place at the beginning of cortical data processing in or near area 17, where the receptive fields are small and extremely precise retinal topography exists; however, interaction and processing of large strabismic angles with ARC most probably take place in the inferotemporal cortex, where the retinal topography is not exact and where large receptive fields exist. Processing for microtropia probably has its site somewhere between those two locations.

## Forms of strabismus

There are many forms of strabismus with different causes. As far back as 1864, Donders [18] showed that accommodative strabismus resulted from convergence due to accommodation for correcting hypermetropia. The accommodative component in mixed esotropia has been studied carefully [19].

The clinical picture of cerebral blindness or syndrome of fixation deficiency in children with strabismus, cerebral palsy, and epilepsy is based on disturbances in the geniculostriate area, eg, on deficient myelination [20\*]. These children are not blind because the second visual pathway to the tectum and from there to the cortex is functioning as substitution for the retino-geniculo-striate pathway.

In the congenital convergent squint syndrome (which occurs in the first 6 months of life with latent nystagmus), dissociated vertical deviation, torticollis, and excyclorotation of the nonfixating eye occur [21]. Using indirect ophthalmoscopy, I very often find that the star is not imaged in the center of the fovea, but nasally to it, before development of latent nystagmus. As the crossed fibers in the chiasma are phylogenetically and ontogenetically older than the uncrossed fibers, it may be logical to assume that the nasal hemiretina is prevalent; this finding may explain a convergent position of the eyes and latent nystagmus. The hope for complete cures therefore in congenital strabismus may be very limited.

I have shown, however, that a complete cure, even on random-dot stereopsis, may be possible in cases of normosensorial late-convergent strabismus with acute onset [22]. This is done by surgery that shows that these cases are of anatomical origin.

On the other hand, primary microtropia is most probably due to a primary sensorial defect that incapacitates the highest grade of binocularity [23]. When combined with hypermetropia, accommodation excess, tendency to convergent position, or amblyopia, primary microtropia may decompensate into a large angle. After treatment, microtropia may come to light again.

Subnormal binocular vision has been defined as "orthotropia or asymptomatic heterophoria with normal retinal correspondence, but foveal suppression in one eye and reduced stereopsis." It is re-

ported as an end result of treatment in infantile esotropia in one article by 4% to 5% [24], and in another article by 18.5% [4]. This finding needs clarification.

Intermittent exotropia may be so resistant to treatment because we do not need binocular stereopsis for distance as much as for near sight. The two-pencil test shows an alignment to orthotropia in some cases of apparently constant exotropia due to the stereoptic task.

## Screening

An objective measurement of small angles of strabismus between 1° and 2.5° with a photographic method based on the first and fourth Purkinje-Sanson mirror images has been proposed [25]. On the other hand, many photoreactive methods have been developed for the detection of refractive errors as amblyogenic factors. These two methods should be complemented by testing for stereopsis with random dots, which can be successful from the age of 6 months; however, some problems will still remain [26].

The obvious deliberations are based on experiences with simple examinations such as those of fixation, correspondence, and stereopsis. There are very sophisticated methods being researched. To quote Hering [27], who is known for his law of equal innervation of yoke muscles and from his law of identical visual direction, it is not the judgment of the physiologist that is crucial, but that of the experienced ophthalmologist.

## References and recommended reading

Papers of particular interest, published within the annual period of review, have been highlighted as:

- Of special interest
  - Of outstanding interest
1. SAKAMOTO: Duke Elder: The System of Ophthalmology. *Acta Soc Ophthalmol Jpn* 1953, 3:119.
  2. TREVARTHEN CB, SPERRY RW: Perceptual Unity of the Ambient Visual Field in Human Commissurotomy. *Brain* 1973, 96:547-570.
  3. HUBEL DH, WIESEL TN: Receptive Field Binocular Interaction and Functional Architecture in the Cats Visual Cortex. *J Physiol* 1962, 160:106.
  4. VON NOORDEN GK, GUNTER K: A Reassessment of Infantile Esotropia. *Am J Ophthalmol* 1988, 105:1-10.
  5. LANG J: New Stereotests. In *Proceedings of the International Symposium on Strabismus, ESA*. Florence: Boschi & Frosini; 1982:177-181.

The two-pencil test and the Lang stereotest are discussed.

6. LANG J, RECHICHI C, STÜRMER J: Natural Versus Haplo-  
•• scopic Stereopsis. *Graefes Arch Clin Exp Ophthalmol* 1991, 229:115-118.

Natural stereopsis is better with large inter pupillary distance, whereas with haploscopic devices, eg, stereoscopy, depth perception is better with a small inter pupillary distance.

7. ELSTON JS, TIMMS C: Clinical Evidence for the Onset of  
• the Sensitive Period in Infancy. *Br J Ophthalmol* 1992, 76:342-345.

There is a latent period of 6 weeks before the onset of the sensitive period.

8. SCHWEERS MA, BAKER J: Comparison of Titmus and Two  
Random-dot Tests in Monofixation. *Am Orthop J* 1992, 42:135-141.
9. HANSELL R: Stereopsis and ARC. *Am Orthop J* 1991, 41:122-127.
10. MANNY RE, MARTINEZ AT, FERN KD: Testing Stereopsis in  
•• the Preschool Child: Is it Clinically Useful? *J Pediatr Ophthalmol Strabismus* 1991, 28:223-231.

None of the children with strabismus passed the Frisby or the Lang stereotest.

11. JULEZ B: *Foundations of Cyclopean Perception*. Chicago: The University of Chicago Press; 1971.
12. PANUM L: *Ueber das Sehen mit Zwei Augen*. Kiel: Schersch-  
che Buchhandlung; 1858.
13. HARDMANN LSJ, SNEAD MP, LOADES J, RUBINSTEIN MP: Mi-  
• crotropia Versus Bifoveal Fixation in Anisometropic Ambly-  
opia. *Eye* 1991, 5:576-584.

Diagnosis of microtropia on the basis of the four-prism test.

14. LANG J, WÜRTH A: Photographic Representation of Anoma-  
lous Retinal Correspondence. *Ophthalmic Res* 1970, 1:88-93.
  15. LANG J: Anomalous Retinal Correspondence Update. *Graef-  
• es Arch Clin Exp Ophthalmol* 1988, 226:137-140.
- Anomalous retinal correspondence has its seat where the retinal topology is not exact and where the binocular receptive fields are very large, such as in Brodmann's areas 20 or 21.

16. JONES EG: The Anatomy of Extrageniculate Visual  
Mechanisms. In *The Neurosciences Third Study Program*.  
Edited by Schmidt FO, Worden FG. Cambridge: MIT Press;  
1974:215-227.
  17. GROSS CG, ROCHA-MIRANDA CE, BENDER DB: Visual Proper-  
ties of Neurons in Inferotemporal Cortex of the Macaque.  
*J Neurophysiol* 1972, 35:96-101.
  18. DONDERERS FC: *The Anomalies of Accommodation and Re-  
fraction of the Eye*. London: New Sydenham Society; 1984.
  19. EDWARD R: The Accommodative Portion of Mixed Es-  
tropia. *J Pediatr Ophthalmol Strabismus* 1991, 28:73-76.
  20. LANG J, FLÜELER U: Fixation Deficiencies in Children With  
• Strabismus, Cerebral Palsy, and Epilepsy. *Klin Monatsbl Augenheilkd* 1988, 192:97-102.
- No foveolar fixation but roving eye movements were seen.
21. LANG J: Squint Dating From Birth or With Early Onset. In  
*First International Congress of Orthoptists*. London: Kimp-  
ton; 1968:231-237.

22. LANG J: Normosensorial Late Convergent Squint. In *Orthoptics, Proceedings of the Fourth International Orthoptic Kongress*. Bern: Kimpton; 1981:230-233.
23. LANG J: Evaluation in Microtropia. In *International Strabismus Symposium Giessen 1966*. Basel: Karger; 1968:219-222.
24. DANNHEIM-DE DECKER E, HAASE W, DE DECKER W: Subnormal Binocular Vision. In *Transactions of the VIIIth International Orthoptic Congress*. Edited by Tillson G. Nürnberg; 1991:172-176.
25. BARRY JAP, EFFERT R, KAUPP A: Objective Measurement of Small Angles of Strabismus in Infants and Children With Photographic Reflection Pattern Evaluation. *Ophthalmology* 1992; 99:320-328.
26. LANG J: Nine Years Experience With the Lang Stereotest. In *Transactions of the VIIIth International Orthoptic Congress*. Edited by Tillson G. Nürnberg: Orthopic Congress; 1991:163-167.
27. HERING E: Ueber Die Anomale Localisation Der Netzhautbilder Bei Strabismus Alternans. *Dtsch Arch für Klin Med* 1899; 64:15-32.

J. Lang, MD, Witikonstrasse 18, CH-8118 Pfaffhausen, Switzerland.